



Review

MINIMALLY INVASIVE OSTEOSYNTHESIS WITH PLATE OR NAIL FOR META-DIAPHYSEAL TIBIAL FRACTURES - WHAT IS BETTER?

B. Makelov*

University Multiprofile Hospital for Active Treatment, Trakia University, Stara Zagora, Bulgaria

ABSTRACT

The aim of this article is to review the surgical techniques for minimally invasive osteosynthesis and associated complications with application of locking compression plates, which have undeniable biomechanical and biological advantages in the treatment of multifragmentary meta-diaphyseal tibial fractures. Unstable proximal tibial fractures include a vast majority of fracture patterns affecting the lower extremities. Most of the fracture types are as a result of high-energy trauma from car accidents, high-altitude injury or motor vehicle incident. Usually, those fractures present with severe soft tissue injury with varying degrees of intra-articular fracture involvement. Intramedullary nailing of tibial fractures as a proven method of biologic fixation and represents one of the most widely used methods for the treatment of unstable fractures involving the proximal meta-diaphyseal area of the tibia, allowing sufficient fracture stability during the early limb movement and weight bearing on the leg. Nevertheless, the complications and technical difficulties in its application raise the question for the choice of an appropriate implant in the treatment of these fracture models in terms of their morphology. Minimally invasive percutaneous plate osteosynthesis with indirect reduction and biologic fixation has the advantage of sparing the local blood flow, even in severely comminuted tibial fracture patterns. The use of pre-contoured locking compression plates for proximal tibia allows stable fixation with good and excellent final clinical results.

Key words: Fractures, MIPPO, Tibia, LCP

INTRODUCTION

The tibia has thin soft tissue coverage in the medial aspect, which is a cause of surgical wound dehiscence and subsequent infection. Delayed healing or non-union due to poor blood supply to the fracture site are also common complications of the operative treatment of the unstable proximal tibial fractures. To avoid these severe complications, a precise operative timing, and staged approach with the goal to restore the local blood tissue perfusion and decreasing the soft tissue oedema in the area of injury is required. Tibial plateau fractures are not part of this review. Unstable proximal tibial fractures include a vast majority of fracture models affecting the lower

limbs. Majority of the fracture types are as a result of high-energy trauma from car accident, altitude injury or motor vehicle incident. Generally, those fractures present with severe soft tissue injury with different degrees of intra-articular involvement. Open reduction and internal fixation according to AO-principles for modern fracture treatment, with one or two LC-DCP plates continues to be a widely used surgical treatment choice, especially in the presence of comminuted distal femoral or patella fractures with unstable proximal tibial fractures (**Figure 1**). The AO foundation has its origins in a Swiss study group named “Arbeitsgemeinschaft für Osteosynthesefragen” (Association of the Study of Internal Fixation-ASIF), commonly referred to as the AO, that was founded in Switzerland in 1958 as a society. In the last few decades, ORIF has been increasingly replaced by modern minimally invasive surgical techniques for

*Correspondence to: *Biser Makelov, University Multiprofile Hospital for Active Treatment, Trakia University, 6003 Stara Zagora, Bulgaria, dr_makelov@hotmail.com*

biologic fracture fixation. These are minimally invasive intramedullary osteosynthesis with contemporary interlocking nails (IMN) and percutaneous plate fixation-MIPO with locking compression plates (LCP). Intramedullary fixation of tibial meta-diaphyseal fractures represents one of the most widely used methods for the treatment of unstable tibial fractures because of its ability to preserve the surrounding soft tissue envelope, allows early movement of the joint, and provide good alignment of the limb, equalization of length discrepancies, and correction of rotation when fixed with blocking screws [1, 2]. However, in contrast to isolated bicondylar tibial fractures, complications such as valgus or apex anterior angulations may occur in unstable proximal meta-diaphyseal tibial fractures, and their incidence reported in the literature can be as high as 58-84% [3-5]. Another common complication of intramedullary fixation is anterior knee pain, which is reported in 31-69% of cases at short-term follow-up, and is particularly troublesome when standing in the squatting position. According to another study,

the pain is also present at long-term follow-up of more than 14 years, with moderate to severe anterior knee pain occurring in 72.3% of cases, projecting from the knee to the anterior aspect of the foot [6]. To address these issues, the entry-point for intramedullary nail placement is determined at the articular surface boundary in the coronal and sagittal planes, in the semi-extended position of the knee and a locking screw is used to reduce the size of the medullary cavity of the proximal metadiaphysis to prevent angular deformity [7, 8]. The use of blocking screws (*pollar*) is indicated to reduce the size of the medullary cavity and to prevent apex-anterior angulation alone or in combination with an accessory plate, where an 8% reduction in malformation rates using these adjunctive techniques has been reported [9-12]. However, these advanced intramedullary fixation techniques are technically more complex with steep learning curve and require specialized instrumentations, and skillful operators are needed.

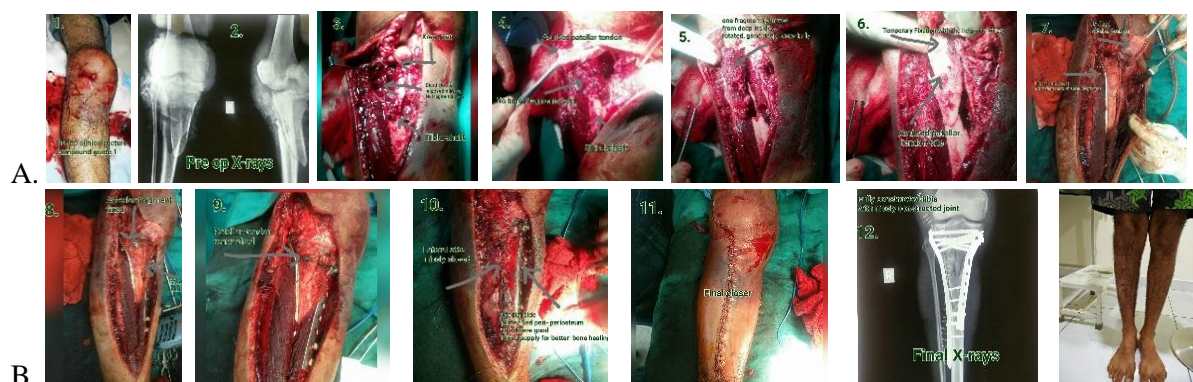


Figure 1. (A, B). A 62 year-old man had a proximal tibial fracture. clinical appearance, diagnostic x-rays and surgical steps-open reduction and open double plating with DCP plates with excellent final clinical outcome. (Courtesy sir R.Tanga)

Another disadvantage of IMN is the significantly increased radiation exposure time in the operating room. But the use of the C-arm and x-ray control in fracture reduction with intra-articular component, is a must, to fulfill the requirements of AO principles for anatomical reconstruction with stable, percutaneous, biological, screw fixation. Complications due to technical pitfalls are not uncommon until the surgical technique becomes familiar to the surgeon [13] (Figure 2A, B, C).

Indirect reduction and biologic fixation has the advantage of not disrupting the local blood flow, even in comminuted fractures. The use of locked precontoured compression plates (LCP-LISS PTP) for proximal tibia allows achieving a stable fixation with good results reported in the literature [14-17]. However, minimally invasive fixation with LCP plate using indirect reduction and stable fixation technique may lead to complications such as delayed bone union with poor limb aligning or even to a non-union at the fracture site.

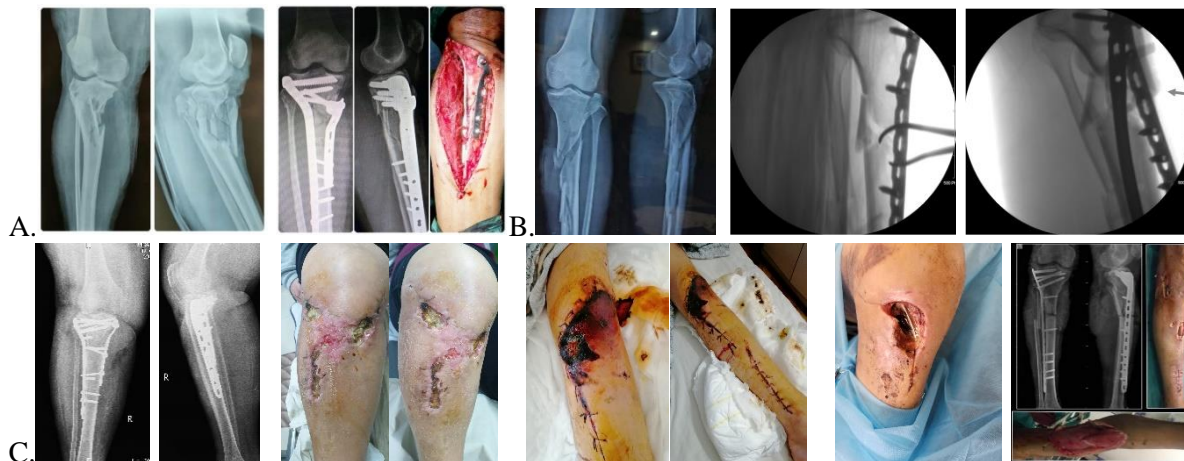


Figure 2. (A) Open reduction and double plate fixation through single incision (B) Unicortical plate was applied to prevent malalignment before IM nailing. After the insertion of a nail, anterior angulation happened with plate pullout (arrow). Minimally Invasive Percutaneous Osteosynthesis (MIPO). (C). Wound complications - from superficial to deep tissue infection.

SURGICAL TECHNIQUE

1 Temporary external fixation.

If the fracture is with a simple morphology due to a low energy injury, without a soft tissue injury, it is most commonly treated with an LCP plate with MIPO. However, proximal tibial fractures are commonly associated with severe soft tissue injury due to high energy trauma. In an open or closed fracture with vascular or neurologic injury a threatening compartment syndrome might be present. Inadequate surgical timing and immediate fracture fixation with an LCP plate can cause further damage to already injured soft tissues and increase the incidence of complications [14, 18, 19]. Therefore, in proximal tibial fractures with significant soft tissue damage, external fixation is used to temporarily stabilize the fracture until local blood flow is restored and soft tissue edema has subsided, marked with the "wrinkle sign." Therefore, in proximal tibial fractures with significant soft tissue damage, external fixation devices are used to temporarily immobilize the fracture until the

soft tissues healed sufficiently to allow a safe MIPO internal fixation with one or two LCP plates (**Figure 3**).

2. Locking compression plate fixation technique.

In MIPO, one or two LC-DCP plates, respectively inserted from medial and lateral side of the proximal tibia or a single lateral LCP plate - factory precontoured for the proximal tibia - is applied. It is necessary to place several screws in the proximal tibia for stable fixation according to the AO principles. In cases where a lateral proximal tibial plate is used, but there is soft tissue damage to the medial cortex, a medial buttress plate should be used for support to the weightbearing medial aspect. The length of the plate should be large enough to provide sufficient stability to the fractured fragments. In comminuted fractures, a plate that is two to three times longer than the fractured zone, is used to safely bridge the fracture site [17].

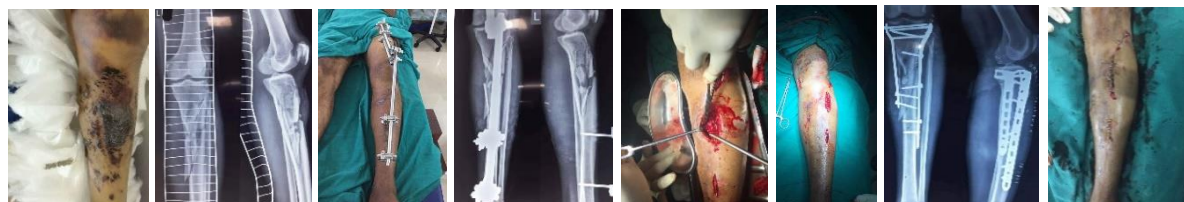

Figure 3. Staged surgery - A 39-year-old man sustained high energy unstable proximal tibial fracture. He had severe soft tissue swelling and skin contusion with bruises and blisters. 10 days later after temporary bridging external fixation, the soft tissue swelling, and blisters subsided - MIPO- double plating is done, as a definitive fracture fixation.

THE PATIENT'S POSITION IN THE OPERATION THEATRE

The patient is placed in the supine position on a standard operating table with a good x-ray control with C-arm placed on the contralateral side. The fracture site is controlled with the C-arm before cleansing of the lower limb and the entire leg is thoroughly disinfected from the iliac crest to the foot. Normally the tourniquet is not needed.

FRACTURE REDUCTION TECHNIQUE

The degree of indirect reduction is controlled under C-arm. Indirect traction by ligamentotaxis using a skeletal traction or distractor is used to achieve spatial alignment of the limb. In oblique fractures, direct intercondylar repositioning can be achieved by ligamentotaxis using a reduction forceps or patellar clamp, and K-wires or cannulated interfragmentary screws are used to fix the achieved indirect reduction. The cannulated screws can be placed percutaneously through stab incisions with blade No.11. **(Figure 4).**

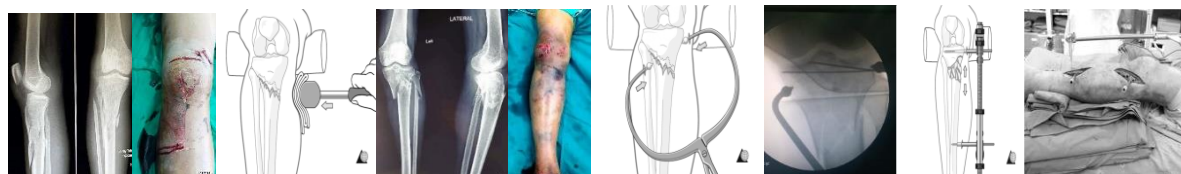

Figure 4. Steps before (manual traction, external bump, clamps, AO-distractor), provisional K-wires used to restore the axial alignment. (from AO surgery reference).

THE LCP -PLATE POSITION AND SCREW FIXATION SEQUENCE

In the presence of an intra-articular fracture component, the articular surface should be anatomically reduced and fixed securely with screws, which will allow early mobilization of the joint. Indirect reposition of the proximal tibial fracture should then be performed. A limited incision of approximately 3 to 5 cm is made on the proximal lateral or medial aspect of the tibia to create a submuscular tunnel. The distal incision is made in the same manner, measuring the length

of the selected plate **(Figure 5 A, B)**. The specific characteristics in the surgical anatomy of the lateral tibial condyle should be counted before plate insertion. It is smaller and situated slightly higher than the medial tibial condyle. If that is not taken into account when placing the lateral LCP plate and if positioned too high, there is a risk for screws penetrating into the medial joint surface **(Figure 5 C)**. The medial proximal tibial angle (MPTA) is an useful parameter for assessment the quality of reduction in the intra-articular component (fig.5.D).

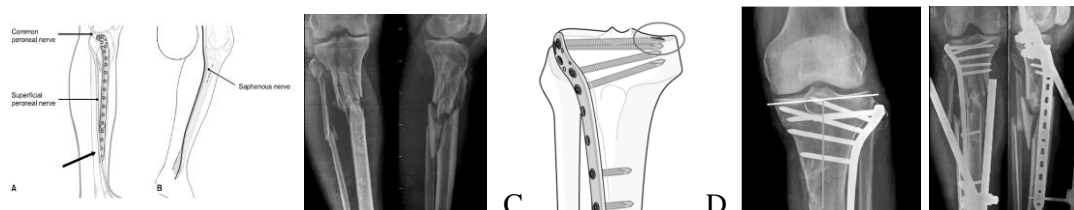


Figure 5. (A) Elongated distal incision is useful to avoid damage to the superficial peroneal nerve (arrow). (B) There is a risk of saphenous nerve injury at proximal medial part (from AO surgery reference). (C) Lateral tibial plateau lies slightly higher than the medial - avoiding intra-articular penetration. (D) MPTA angle measurement for adequate axial alignment restoration (from AO surgery reference).

After confirming the optimal proximal position of the LCP plate, temporary fixation is performed with a K-wire in both ends of the plate. After temporary fixation of the plate with K-wires, its proper alignment to the bone is confirmed by anterior-posterior and lateral x-ray verification by the C-arm. The lateral proximal tibial LCP plate can be fixed with four to five locking screws at the proximal end,

using screws of the greatest possible length. Distally, three to four locking screws should be placed under the fracture site. A bicortical screw placement and fixation at appropriate intervals, for the proximal screw group, respectively same number distal bicortical screws with one last, monocortical screw **(Figure 6).**

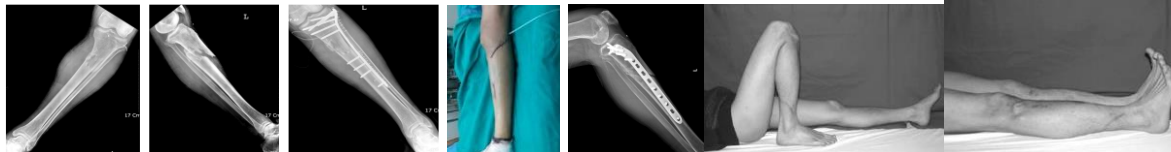

Figure 6. A 48-year-old man with proximal tibial fracture was treated with percutaneous plating using LCP-PLT on the lateral side. After operation, a good alignment was achieved on coronal and sagittal planes. The fracture healed 20 weeks after operation. An excellent final outcome.

If the proximal fragment is small and comminuted, the lateral plate fixation is not stable enough and an inter condylar fracture might occur, if there is no medial support. The fractured medial cortex can be fixed with screws or with a medial buttress plate. Double plating with accessory medial buttress plate achieves a stronger fixation and does not require osteoplasty. Intraoperatively, electro cautery cable – The Bowie technique is used to check the alignment in the coronal and sagittal planes with the C-arm control [20]. The final check of the rotational alignment is done by comparing the knee and the tarsal joint with the contra-lateral side [21].

POSTOPERATIVE PROTOCOL

Exercises to strengthen the quadriceps muscle and active movements of the operated lower limb, as tolerated, start on the next day after the operation. Lifting exercises began from the third post-operative day and continued after hospital discharge. Active knee exercises are encouraged either. Weightbearing depends on the type of fracture and degree of fixation stability, but once determined that stable fixation has been achieved, PWB starts with touch-toe walking, usually 4 to 6 weeks after the surgery. Full weight bearing of the limb should commence after the 3rd month, depending on radiological confirmations of the degree of bone union.

COMPLICATIONS

(1) Malalignment. During minimally invasive LCP plate fixation of proximal tibial fractures, the incidence of postoperative deformity has been reported to be between 0 - 23% [22-25]. Malalignment incidence rate with MIPO is lower than intramedullary fixation and can be lowered with careful surgical technique [3, 4, 26].

(2) Infection: According to recent studies [4, 22, 23, 25-28], the incidence rate of superficial infection is between 0 - 6%, while the incidence of deep infection is 0-3%, but another author [18]

reported a relatively high incidence of deep infection of up to 22%, suggesting that in high-energy proximal tibial fractures, even with minimally invasive plate fixation a difficult-to-treat, deep infections are possible.

(3) Hardware irritation: In several recent publications indicate that 5-18% of patients report irritation and discomfort that necessitates removal of the implants [22, 23, 25-28]. Development of metal instrumentation with sufficient strength and low profile may reduce the incidence of irritation.

(4) Metal breakage: A single lateral LCP plate for unstable proximal tibia fractures with critical size bone defect at the fracture site, may not accomplish optimal stability. A single plate is not enough to achieve a solid fixation, especially if the periosteum is ruptured as in open fracture situation. There is always a delay in the osseointegration and early FWB may cause fracture of the hardware. To prevent that, a double plating technique should be used, and if a bone defect is present, fixation with a medial buttress plate and early osteoplasty must be performed. In elderly patients, controlled PWB is not possible.

(5) Delayed consolidation and debricollage of the osteosynthesis: According to literature, delayed bone union and no-union at fracture site had a relatively low incidence of 0-5% [19, 22-28]. This is due to the fact that the minimally invasive operative techniques, preserve intact the blood supply to the injured bone segment, resulting in a high rate of osseointegration.

CONCLUSION

Minimally invasive plate osteosynthesis as a preferred surgical treatment method for multifragmentary proximal tibial fractures. It is less complex than intramedullary fixation and allows stable fixation, and early joint mobilization after optimal fracture reduction in the coronal and sagittal plane, with low rate of complications, malunion and limb length discrepancies. The minimally invasive techniques diminish damage

to the surrounding soft tissues, and preserve the blood supply at the fracture site, thus increasing the rate of osseointegration with low rate of deep infections. Minimally invasive plate osteosynthesis is an appropriate, biologically sparing method of treatment, when compared to intramedullary nailing.

REFERENCES

1. Asche G: Result of the treatment of femoral and tibial fractures following interlocking nailing and plate osteosynthesis. A comparative retrospective study. *Zentralblatt Fur Chirurgie*, 114: 1146-1154, 1989.
2. Johner R, Wruhs O: Classification of tibial shaft fractures and correlation with results after internal fixation. *Clin Orthop*, 178: 7-25, 1983.
3. Garnavos C. Intramedullary Nailing with a Suprapatellar Approach and Condylar Bolts for the Treatment of Bicondylar Fractures of the Tibial Plateau. *JBJS Open Access*, Apr 18;2(2): e0017. doi: 10.2106/JBJS.OA.16.00017. PMID: 30229216; PMCID: PMC6132469, 2017
4. Johnson KD: Management of malunion and nonunion of the tibia. *Orthop Clin North Am*, 18: 157-171, 1987.
5. Safran O, Liebergall M, Segal D, Mosheiff R: Proximal tibial fractures-should we nail them? *Am J Orthop*, 30: 681-684, 2001. 22) Schutz M, KMJ, Haas N: Stabilization of proximal tibial fractures with the LIS-System: early clinical experience in Berlin. *Injury*, 34 (Suppl 1): A30-35, 2003.
6. Lefavre KA, Guy P, Chan H, Blachut PA: Long-term follow-up of tibial shaft fractures treated with intramedullary nailing. *J Orthop Trauma*, 22: 525-529, 2008.
7. Buehler KC, Green J, Woll TS, Duwelius PJ: A technique for intramedullary nailing of proximal third tibiafractures. *J Orthop Trauma*, 11: 218-223, 1997.
8. Freedman EL, Johnson EE: Radiographic analysis of tibial fracture malalignment following intramedullary nailing. *Clin Orthop Relat Res*, 315: 25-33, 1995.
9. Dunbar RP, Nork SE, Barei DP, Mills WJ: Provisional plating of type III open tibia fractures prior to intramedullary nailing. *J Orthop Trauma*, 19: 412-414, 2005.

MAKELOV B.

10. Krettek C, Miclau T, Schandelmaier P, Stephan C, Möhlmann U, Tscherne H: The mechanical effect of blocking screws ("Poller screws") in stabilizing tibia fractures with short proximal or distal fragments after insertion of small-diameter intramedullary nails. *J Orthop Trauma*, 13: 550-553, 1999.
11. Ricci WM, O'Boyle M, Borrelli J, Bellabarba C, Sanders R: Fractures of the proximal third of the tibial shaft treated with intramedullary nails and blocking screws. *J Orthop Trauma* 15: 264-270, 2001.
12. Nork SE, Barei DP, Schildhauer TA, et al: Intramedullary nailing of proximal quarter tibial fractures. *J Orthop Trauma*, 20: 523-528, 2006.
13. Phisitkul P, Mckinley TO, Nepola JV, Marsh JL: Complications of locking plate fixation in complex proximal tibia injuries. *J Orthop Trauma*, 21: 83-91, 2007.
14. Kim JW, Oh CW, Oh JK, et al: Staged minimally invasive plate osteosynthesis of proximal tibial fracture. *J Korean Fracture Soc*, 22: 6-12, 2009.
15. Oh CW, Oh JK, Jeon IH, et al: Minimally invasive percutaneous plate stabilization of proximal tibial fractures. *J Korean Fracture Soc*, 17: 224-229, 2004.
16. Schutz M, Kääh MJ, Haas N: Stabilization of proximal tibial fractures with the LIS-System: early clinical experience in Berlin. *Injury*, 34(Suppl 1): A30-35, 2003.
17. Stannard JP, Wilson TC, Volgas DA, Alonso JE: Fracture stabilization of proximal tibial fractures with the proximal tibial LISS: early experience in Birmingham, Alabama (USA). *Injury*, 34(Suppl 1): A36-42, 2003
18. Tscherne H, Lobenhoffer P: Tibial plateau fractures. Management and expected results. *Clin Orthop Relat Res*, 292: 87-100, 1993.
19. Watson JT: High-energy fractures of the tibial plateau. *Orthop Clin North Am*, 25: 723-752, 1994.
20. Krettek C, Miclau T, Grn O, Schandelmaier P, Tscherne H: Intraoperative control of axes, rotation, and length in femoral and tibial fractures. Technical note. *Injury*, 29(Suppl 3): C29-39, 1998.
21. Yazdi H, Taher Ghaderi M, Yousof Gomrokchi A, Pezeshk P. A New Radiographic Method for Estimating Tibial Malrotation. *J. Res. Orthop. Sci.*; 7 (3) :121-

128. <http://jros.iums.ac.ir/article-1-2115-en.html>, 2020.
22. Cole PA, Zlowodzki M, Kregor PJ: Treatment of proximal tibia fractures using the less invasive stabilization system: surgical experience and early clinical results in 77 fractures. *J Orthop Trauma*, 18: 528-535, 2004.
23. Egol KA, Su E, Tejwani NC, Sims SH, Kummer FJ, Koval KJ: Treatment of complex tibial plateau fractures using the less invasive stabilization system plate: clinical experience and a laboratory comparison with double plating. *J Trauma*, 57: 340-346, 2004.
24. Gosling T, Schandelmaier P, Muller M, Hankemeier S, Wagner M, Krettek C: Single lateral locked screw plating of bicondylar tibial plateau fractures. *Clin Orthop Relat Res*, 439: 207-214, 2005.
25. Ricci WM, Rudzki JR, Borrelli J Jr: Treatment of complex proximal tibia fractures with the less invasive skeletal stabilization system. *J Orthop Trauma*, 18: 521- 527, 2004.
26. Tornetta P 3rd, Collins E: Semiextended position of intramedullary nailing of the proximal tibia. *Clin Orthop Relat Res*, 328: 185-189, 1996.
27. Boldin C, Fankhauser F, Hofer HP, Szyszkowitz R: Three-year results of proximal tibia fractures treated with the LISS. *Clin Orthop Relat Res*, 445: 222-229, 2006.
28. Stannard JP, Wilson TC, Volgas DA, Alonso JE: The less invasive stabilization system in the treatment of complex fractures of the tibial plateau: shortterm results. *J Orthop Trauma*, 18: 552-558, 2004.

MAKELOV B.